


cambridge.org/cty

Claire McGinn<sup>1,2</sup> , Rehab Agouba<sup>1</sup>, Siobhan O'Sullivan<sup>1</sup>, Deirdre Donnelly<sup>1</sup> and Frank Casey<sup>1,2</sup>

<sup>1</sup>Royal Belfast Hospital for Sick Children, Belfast, UK and <sup>2</sup>Queen's University Belfast, UK

## Brief Report

**Cite this article:** McGinn C, Agouba R, O'Sullivan S, Donnelly D, and Casey F (2025) PPA2-associated cardiac arrest survivor. *Cardiology in the Young* **35**: 433–435. doi: [10.1017/S1047951125000174](https://doi.org/10.1017/S1047951125000174)

Received: 10 July 2024

Revised: 28 September 2024

Accepted: 29 December 2024

### Keywords:

genetic; cardiac arrest; fibrosis

### Corresponding author:

Claire McGinn; Email: [Cmcginn09@qub.ac.uk](mailto:Cmcginn09@qub.ac.uk)

### Abstract

Biallelic pathogenic variants in the inorganic pyrophosphatase 2 (PPA2) gene are a rare but established cause of sudden infant death, which may be precipitated by a pyrexial or viral illness. It has also been associated with sudden death secondary to alcohol ingestion in young adults. We describe the case of a thirteen-month-old female who presented following out-of-hospital cardiac arrest and was subsequently diagnosed with compound, heterozygous pathogenic variants of PPA2. She survived this episode and made excellent neurological recovery despite her prolonged out-of-hospital resuscitation. This case describes her initial presentation, consideration of PPA2-related cardiac arrest in the differential diagnosis, and the subsequent secondary preventative strategies. These included insertion of an implantable cardiac defibrillator, avoidance of alcohol in her medication preparations and administration of childhood vaccinations in a hospital environment due to risk of pyrexia-induced arrhythmias.

## Introduction

Biallelic pathogenic variants in the inorganic pyrophosphatase 2 (PPA2) gene are a rare but established cause of sudden infant death, which may be precipitated by a pyrexial or viral illness. It has also been associated with sudden death secondary to alcohol ingestion in young adults. Guimeir et al described 34 individuals with PPA2 variants from 20 families who were affected by sudden cardiac death and acute heart failure. Where available their histology/cardiac MRI frequently demonstrated evidence of myocardial fibrosis.<sup>1</sup> PPA2 encodes the mitochondrial pyrophosphatase that hydrolyses inorganic pyrophosphate into two orthophosphate molecules (OMIM: 609988). However, how inorganic pyrophosphatase deficiency results in organ dysfunction is not yet fully understood. Studies in yeast models highlight that deletion of the PPA2 gene causes loss of mitochondria and subsequent cell death.<sup>2</sup> It is hypothesised that accumulation of inorganic pyrophosphates beyond a certain threshold impacts the mitochondrial membrane potential and certain triggers, e.g alcohol, may increase stress and result in a life-threatening arrhythmia.<sup>3</sup>

Unfortunately, most diagnoses of PPA2 mutation have been post-mortem or from family cascade screening of affected deceased individuals. Zhao et al described a surviving child diagnosed with PPA2 mutation at 2.5 years following genetic testing for acute heart failure. She first presented with viral infections and seizure activity. An echocardiogram demonstrated impaired cardiac function. By 4 years of age, she had evidence of myocardial fibrosis on cardiac MRI. She was managed medically with diuretics, vasodilators, coenzyme Q10, and anticonvulsants.<sup>4</sup> Sanford et al describe the case of a 5-week-old male with vocal cord paralysis who died following sudden cardiac arrest and PPA2 mutation was diagnosed from his newborn screening bloodspot. His initial post-mortem did not demonstrate evidence of cardiac fibrosis.<sup>5</sup>

## Clinical presentation

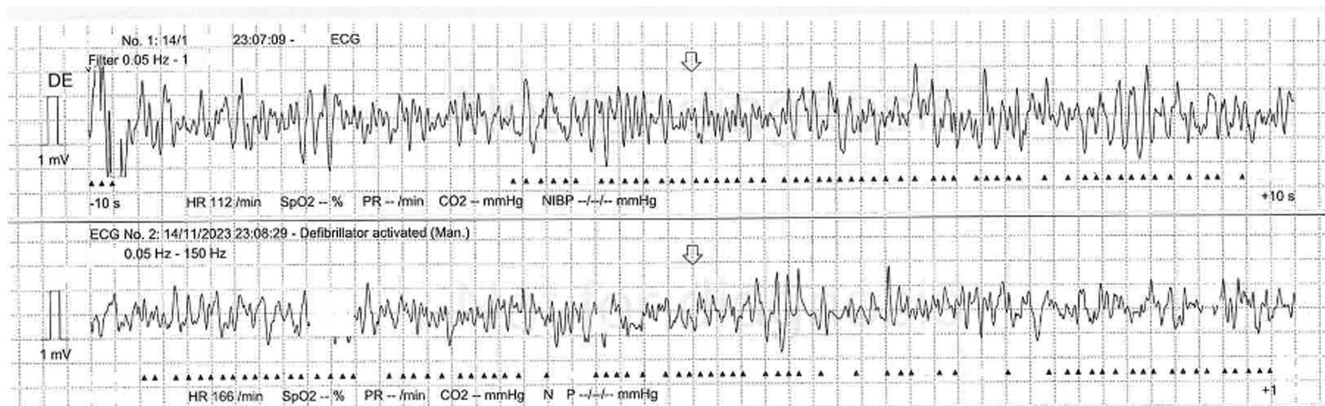
We describe the case of a thirteen-month-old female who presented following out-of-hospital cardiac arrest and was subsequently diagnosed with compound, heterozygous pathogenic variants of PPA2. She was found unresponsive by her parents in bed after a mild viral illness over the preceding days. Her parents commenced cardiopulmonary resuscitation and ambulance staff confirmed ventricular fibrillation (Fig 1) and delivered a shock resulting in pulseless electrical activity. Chest compressions and adrenaline boluses were continued for 45 minutes until spontaneous return of circulation. Her venous blood gas on arrival to hospital demonstrated a metabolic acidosis, NT-proBNP 2534ng/L, troponin 324 ng/L, C reactive protein 252 mg/L, haemoglobin 109 g/L, white cell count 20.8x10<sup>9</sup>/L, platelets 240x10<sup>9</sup>/L, and ammonia 24umol/L. Her renal function and electrolytes were normal. Electrocardiograph (ECG) demonstrated normal sinus rhythm with no obvious abnormalities (Fig 2). Differentials at this point included sepsis, myocarditis, and aspiration event.

She had an echocardiogram which demonstrated a structurally normal heart with moderately reduced left ventricular function. She was initially treated with broad-spectrum

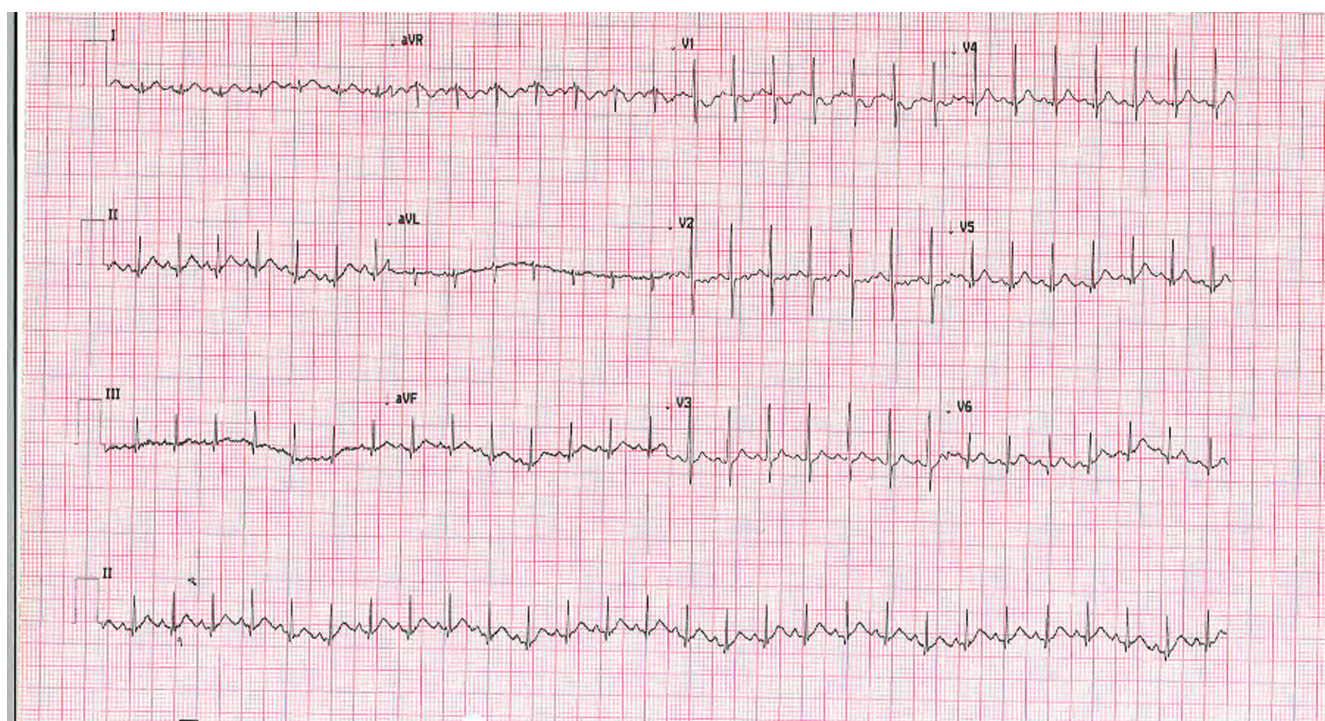
© The Author(s), 2025. Published by Cambridge University Press. This is an Open Access article, distributed under the terms of the Creative Commons Attribution licence (<https://creativecommons.org/licenses/by/4.0/>), which permits unrestricted re-use, distribution and reproduction, provided the original article is properly cited.



CAMBRIDGE  
UNIVERSITY PRESS



**Figure 1.** Initial rhythm strip demonstrating ventricular fibrillation.



**Figure 2.** 12 lead ECG on arrival to hospital demonstrating normal sinus rhythm.

intravenous antibiotics, intravenous antiviral therapy, and managed with neuroprotective strategies. Her blood, cerebrospinal fluid, and urine cultures demonstrated no growth. Positive testing for parainfluenza virus from bronchoalveolar lavage. She was extubated eight days following presentation and quickly weaned off sedation. There was evidence of hypoxic brain injury on MRI brain, which was supported by her clinical symptoms of dystonic episodes and increased tone in her upper limbs. Her electroencephalogram suggested findings consistent with an encephalopathic process and this was managed conservatively with anticholinergics and anticonvulsants.

Cardiac MRI was performed seven days post-cardiac arrest. This showed a structurally normal heart with mildly impaired left ventricular function (ejection fraction = 52%), normal right ventricular function, and no evidence of delayed myocardial enhancement to suggest fibrosis. She remained on continuous

cardiac rhythm monitoring, which was predominantly sinus rhythm with infrequent monomorphic ventricular ectopic beats.

### Genetics

Rapid trio whole exome sequencing diagnosed compound heterozygous, pathogenic missense variants in PPA2. Biallelic inheritance was confirmed; the paternal variant was NM\_176869.3: c.380G>T; p.(Arg127Leu) and the maternal variant was NM\_176869.3: c.514G>A; p.(Glu172Lys). Both parental variants have been previously described in the literature. No additional sequence variants, or copy-number variants, were identified by exome sequencing and single nucleotide polymorphism microarray was normal. Predictive testing of the proband's sister, aged 4 years 9 months, showed that she did not carry either variant.



## Management and outcome

The patient was reviewed by specialist paediatric metabolic, genetic, neurology, and cardiology teams. After twelve days in intensive care, she was transferred to the ward for neuro-rehabilitation. She had cardiac monitoring throughout her inpatient stay without evidence of arrhythmia but because of the risk of future tachyarrhythmias, she was commenced on beta blockers and referred for implantable cardiac defibrillator. She was also trialled on Coenzyme Q10, but this was poorly tolerated and subsequently stopped. Due to the available literature regarding PPA2-associated mitochondrial disease's low alcohol tolerance, and risk of arrhythmia, each of her medications required special preparations which excluded alcohol. When this patient received a small dose of propranolol prepared with alcohol, she had immediate severe vomiting.

The patient had her vaccinations administered in hospital due to risk of pyrexia post-vaccination and potential arrhythmia at home. She was discharged home eight weeks following her first presentation with an external cardiac defibrillator and parental training in basic life support as she awaited the date for implantable cardiac defibrillator. On discharge, she had regained significant motor milestones including sitting supported, smiling, and interacting but her swallow remained a concern and she was discharged with nasogastric feeds and ongoing physiotherapy, speech, and occupational therapy input. Her echocardiogram showed recovery of left ventricular function with mild left ventricular dilatation. She was briefly readmitted and underwent insertion of an implantable cardioversion device at 16 months old without complication.

## Conclusion

This thirteen-month female diagnosed, with compound heterozygous pathogenic, missense variants of PPA2 survived a cardiac arrest secondary to ventricular fibrillation. She demonstrated encouraging short-term neurological and cardiac recovery and was subsequently accepted for implantable cardiac defibrillator. This device is not without its own potential issues including lead migration, inappropriate shocks, and long-term replacement requirements, but given the current available literature appears

the most appropriate management. Interestingly, unlike most other PPA2 p. Glu172lys variant mutation presentations<sup>5</sup>, this patient did not demonstrate evidence of cardiac fibrosis at presentation and her ventricular function has largely recovered following the initial insult. This will require close evaluation of cardiac function over time and her parents have been counselled that she may have further deterioration in her cardiac status in the future.

## Key learning points

1. Perform urgent genetic testing in the case of unexplained out-of-hospital cardiac arrest.
2. Implantable cardiac defibrillators are viable secondary preventative strategies for small children under 10kg.

**Financial support.** Dr Claire McGinn's salary as a research fellow is funded through the Royal Belfast Hospital for Sick Children charitable funds. There was no other funding for the other authors in relation to this paper.

**Consent declaration.** The parents of this patient have provided written consent for the publication of her case information for educational purposes.

## References

1. Guimier A, Achleitner MT, Moreau de Bellaing A, et al. PPA2-associated sudden cardiac death: extending the clinical and allelic spectrum in 20 new families. *Genet Med* 2021 Dec; 23-24: 2415-967-2425. DOI: [10.1038/s41436-021-01296-6](https://doi.org/10.1038/s41436-021-01296-6) Erratum in: *Genet Med*. 2022 Apr.
2. Guimier A, Gordon CT, Godard F, et al. Biallelic PPA2 mutations cause sudden unexpected cardiac arrest in infancy. *Am J Hum Genet* 2016; 99: 666-673. DOI: [10.1016/j.ajhg.2016.06.021](https://doi.org/10.1016/j.ajhg.2016.06.021).
3. Kennedy H, Haack TB, Hartill V, et al. Sudden cardiac death due to deficiency of the mitochondrial inorganic pyrophosphatase PPA2. *Am J Hum Genet* 2016; 99: 674-682. DOI: [10.1016/j.ajhg.2016.06.027](https://doi.org/10.1016/j.ajhg.2016.06.027).
4. Zhao A, Shen J, Ding Y, et al. Long-read sequencing identified a novel nonsense and a de novo missense of PPA2 in trans in a chinese patient with autosomal recessive infantile sudden cardiac failure. *Clin Chim Acta* 2021; 519: 163-171. DOI: [10.1016/j.cca.2021.03.029](https://doi.org/10.1016/j.cca.2021.03.029).
5. Sanford E, Jones MC, Brigger M, et al. Postmortem diagnosis of PPA2-associated sudden cardiac death from dried blood spot in a neonate presenting with vocal cord paralysis. *Cold Spring Harb Mol Case Stud*; 6: a005611. DOI: [10.1101/mcs.a005611](https://doi.org/10.1101/mcs.a005611).