

questionnaires and structural magnetic resonance imaging (MRI) data were acquired on a 3T Siemens scanner. A surface-based analysis was conducted using the Computational Anatomy Toolbox (CAT12) in Statistical Parametric Mapping (SPM12). Partial correlation analysis was also performed using R software to investigate the association between the LGI values extracted from the region of interest (ROI) and clinical symptoms, including depression, anxiety, emotion dysregulation, and anhedonia in individuals with NSSI.

Results: Individuals with NSSI showed significantly increased LGI in the right insula sulcus and left superior temporal sulcus (STS), along with decreased LGI in the right calcarine and left superior parietal sulcus (SPS), compared to controls (5000 permutation correction, threshold-free cluster enhancement with a threshold of $p < .05$). In addition, higher LGI in left STS was correlated with greater scores of the Beck Anxiety Inventory ($r = 0.22$, $p < .05$) and of the Impulse Control Difficulties subscale of the Difficulties in Emotion Regulation Scale ($r = 0.34$, $p < .001$). Conversely, reduced LGI of the right calcarine was associated with a higher score on the Anhedonia subscale of the Beck Depression Inventory ($r = -0.23$, $p < .05$) within individuals with NSSI.

Conclusions: This study identified hypergyria in the right insular and left STS and hypogyria in the right calcarine and left SPS in individuals with NSSI. The former pattern was associated with anxiety and impulse control difficulties, and the latter was with anhedonia. This study is the first to alter distinct neurodevelopmental patterns of local gyrification and their correlations with clinical manifestations in individuals with NSSI.

Disclosure of Interest: None Declared

EPV0625

Brain correlates of recall of negative autobiographical memories in patients with schizophrenia

L. Barbosa^{1*}, A. Aquino-Servín¹, P. Fuentes-Claramonte^{1,2}, M. Á. García-León^{1,2}, A. Karuk¹, N. Jaurrieta³, B. Hoyas-Galán⁴, N. Ramiro-Sousa⁵, C. Corte-Souto⁶, P. McKenna^{1,2} and E. Pomarol-Clotet^{1,2}

¹Neuroimaging, FIDMAG Sisters Hospitaliers Research Foundation;

²Schizophrenia, CIBERSAM, ISCIII, Barcelona; ³Psychology, Hospital Sagrat Cor, Martorell; ⁴Nursing, Hospital General de Granollers, Granollers; ⁵Psychology, Hospital Sant Rafael and ⁶Psychology, CSMA Vila de Gràcia-Cibeles, Barcelona, Spain

*Corresponding author.

doi: 10.1192/j.eurpsy.2024.1286

Introduction: Autobiographical memory is known to be disturbed in schizophrenia. In addition, a leading theory of auditory hallucinations (AVH) is that they are intrusive – typically negative – autobiographical memories that are misinterpreted as perceptions.

Objectives: The aim of this study was to examine the brain functional correlates of recall of negatively emotionally valenced

autobiographical memories in patients with schizophrenia, with a longer term aim of comparing patients with and without AVH.

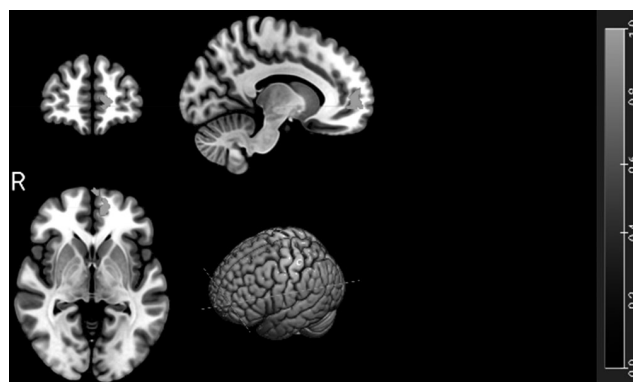
Methods: 11 patients meeting DSM-5 criteria for schizophrenia or schizoaffective disorder and 10 age, sex and estimated premorbid IQ-matched healthy controls have so far taken part.

Participants underwent functional MRI in a 3T scanner while performing a task requiring them to recall autobiographical memories in response to individually tailored pairs of cue words. The cue words were based on autobiographical memories previously elicited in an interview with each patient and were designed to evoke the same memory. The cue words were presented in 10 20-second blocks interspersed with blocks where the subjects viewed cue words that did not evoke autobiographical memories. Brain activations were examined in three contrasts of interest: memory evoking words vs baseline, neutral words vs baseline and memory evoking vs neutral words.

Pre-processing and analysis were carried out with the FEAT module included in the FSL software. Statistical analysis was performed by means of a General Linear Model (GLM) approach.

Results: In the memory evoking vs baseline contrast the patients showed hypoactivation in the medial frontal cortex compared to the healthy controls (Figure 1). There were no differences in activation between the patients and the controls comparing the memory evoking and neutral cues.

Image:



Conclusions: The finding of hypoactivation in the medial frontal cortex compared to low level baseline in patients with schizophrenia suggests dysfunction in the default mode network, which is known to activate during recall of autobiographical memories.

These preliminary results suggest that recall of negative autobiographical memories in patients with schizophrenia is associated with reduced activity in the default mode network. A planned larger sample of patients and controls will be used to examine activations in patients with and without AVH.

Disclosure of Interest: None Declared