



## Neuroimaging Highlight

# Internal Carotid Arteritis Associated with Sinusitis in a Child: Potential Benefit of Corticosteroids

Ryan Gotfrit<sup>1</sup> , Nagwa Wilson<sup>2</sup>, Maryanne Matzinger<sup>2</sup> and Hugh J. McMillan<sup>3</sup> 

<sup>1</sup>Department of Medicine, Division of Neurology, The Ottawa Hospital, Ottawa, Ontario, Canada, <sup>2</sup>Department of Medical Imaging, Children's Hospital of Eastern Ontario, University of Ottawa, Ottawa, Ontario, Canada and <sup>3</sup>Department of Pediatrics, Division of Neurology, Children's Hospital of Eastern Ontario, University of Ottawa, Ottawa, Ontario, Canada

**Keywords:** Arteritis; intracranial thrombosis; ischemic stroke; *Streptococcus intermedius*; thrombosis; prednisone

(Received 18 March 2024; final revisions submitted 3 September 2024; date of acceptance 12 September 2024; First Published online 25 October 2024)

An 8-year-old girl presented with a 12-day history of progressive headache, fever, rhinorrhea and periorbital swelling. She was febrile with lethargy and nuchal rigidity. Her neurological exam noted bilateral oculomotor deficits in all directions consistent with cranial nerve III, IV and VI palsies. She had a normal afferent visual exam. She had decreased facial sensation to the left V1 territory. She had no other neurological deficits. Clinically, she was suspected to have sinusitis, meningitis and cavernous sinus thrombosis. MRI with gadolinium confirmed bilateral sphenoid and ethmoid sinusitis, thrombophlebitis of the cavernous sinuses and right internal jugular and right superior ophthalmic veins. MR angiogram revealed narrowing of both internal carotid arteries (ICA) at the petrous and cavernous segments with contrast studies showing narrowing and wall enhancement suggestive of arteritis (Figure 1). She received empiric intravenous (IV) ceftriaxone, metronidazole and vancomycin. Ceftriaxone was continued via a peripherally inserted central catheter (×6 weeks treatment). Metronidazole IV was administered (×10 days) followed by an additional 34 days of oral therapy. Vancomycin IV was stopped after 3 days when blood culture and sensitivities returned. Heparin IV was started, transitioned to enoxaparin prior to discharge and discontinued after resolution of the thrombus. Otolaryngology performed an urgent sinus decompression surgery. Lumbar puncture demonstrated a normal opening pressure with CSF leukocytes  $25 \times 10^6$  cells/L (normal  $<5 \times 10^6$  cells/L) and normal CSF erythrocytes, protein and glucose. Blood culture (drawn prior to antibiotics) identified *Streptococcus intermedius*. Given her ICA narrowing and evidence for arteritis, and following a lack of clinical improvement after 24 hours of antibiotics, infectious disease consultation and consideration of potential risk/benefit, she was treated with methylprednisolone 30 mg/kg/day IV (×5 days) followed by an oral prednisone taper over 4 weeks. Two days after treatment, she showed improvement in periorbital swelling and

resolution of fever, meningismus and facial sensory deficit as well as near-complete resolution of her oculomotor deficits. She was discharged home after 10 days.

Repeat imaging 8 weeks later demonstrated resolution of her right ICA narrowing and mild residual left ICA narrowing. Her right internal jugular and superior ophthalmic vein thrombi had resolved. Her neurological examination was normal. A complete thrombotic workup revealed a heterozygous variant for F5 p. Arg534Gln (Factor V Leiden).

Over one-third of children with acute bacterial meningitis show MRI evidence of an acute ischemic stroke (AIS).<sup>1</sup> Pneumococcal meningitis has been associated with AIS in 48% of children and 36% of adults.<sup>1,2</sup>

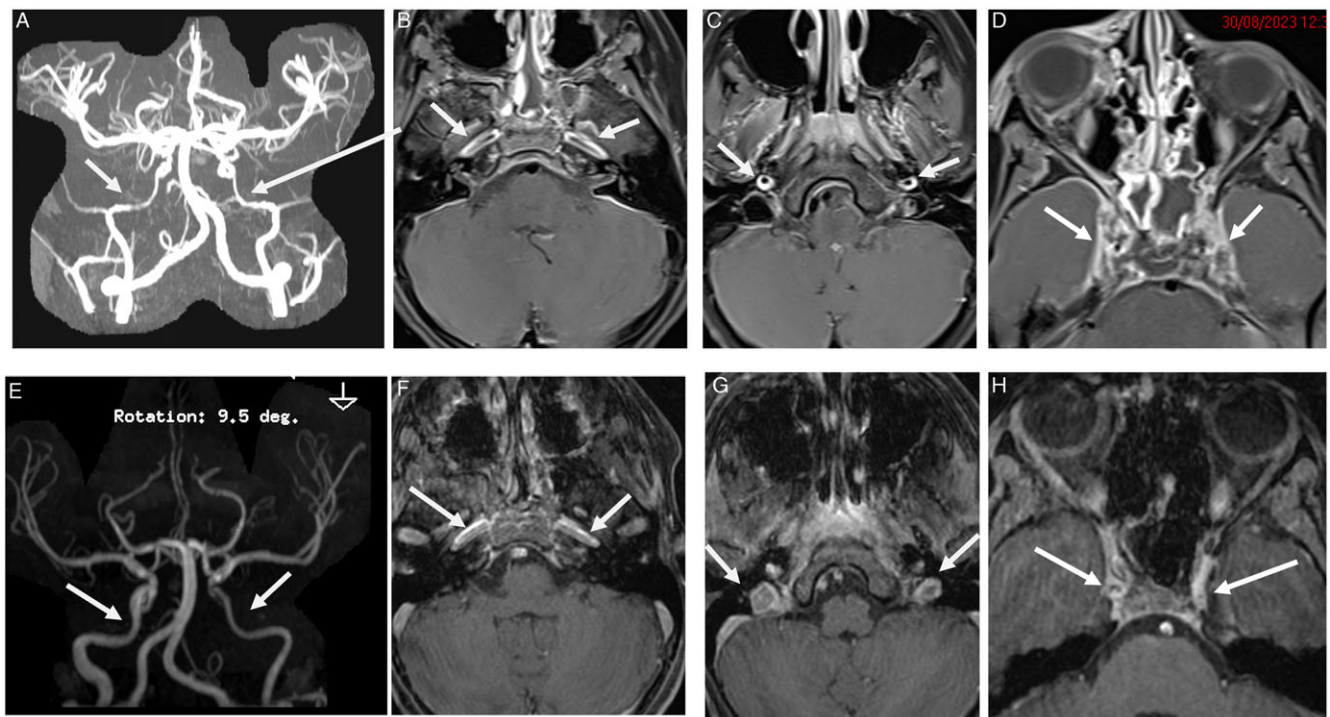
Infectious vasculitis has been reported in a child and adults with pneumococcal meningitis.<sup>3,4</sup> The child demonstrated AIS with resulting vasculitis in the first week after initiation of antibiotics.<sup>3</sup> There are reports of adults with pneumococcal meningitis who demonstrate delayed AIS with vasculopathy who, after an initial clinical improvement, abruptly declined 7–19 days later. Arteriopathy involving large and small penetrating arteries is documented in adults with pneumococcal meningitis.<sup>5–7</sup>

Corticosteroid use has been associated with reduced mortality in pneumococcal meningitis and clinical/radiologic improvement in presumed central nervous system (CNS) vasculitis in the context of *Streptococcus pneumoniae* meningitis complicated by ischemic stroke;<sup>11</sup> however, there are no guidelines regarding their use in patients with MRI evidence of vessel involvement. We demonstrate a case where MR angiogram was essential to the diagnosis of CNS infectious vasculitis, the hallmarks of which are vessel wall enhancement and arterial stenoses.<sup>12</sup> As such, we illustrate that the use of vascular imaging in the setting of head and neck infections is useful for assessing stroke risk in these cases. Further, our decision to treat with corticosteroids (as well as the dose and taper schedule

**Corresponding author:** Ryan Gotfrit; Email: [rgotf020@uottawa.ca](mailto:rgotf020@uottawa.ca)

**Cite this article:** Gotfrit R, Wilson N, Matzinger M, and McMillan HJ. (2025) Internal Carotid Arteritis Associated with Sinusitis in a Child: Potential Benefit of Corticosteroids. *The Canadian Journal of Neurological Sciences* 52: 514–516, <https://doi.org/10.1017/cjn.2024.313>

© The Author(s), 2024. Published by Cambridge University Press on behalf of Canadian Neurological Sciences Federation. This is an Open Access article, distributed under the terms of the Creative Commons Attribution licence (<http://creativecommons.org/licenses/by/4.0/>), which permits unrestricted re-use, distribution and reproduction, provided the original article is properly cited.



**Figure 1.** (a) MRA time of flight (ToF) demonstrates significant narrowing of the petrous and cavernous segments of ICA on both sides (arrows); (b–c) axial T1WI with fat saturation (FS) and gadolinium (Gd) shows bilateral wall thickening and enhancement of the same segments of ICA and (d) demonstrates distended enhancement of the cavernous sinus on both sides, more prominent on the right side with small filling defects within. Follow-up MRI 1.5T after 8 weeks: (e) MRA ToF demonstrates resolution of the narrowing of the petrous and cavernous segments of the right ICA residual narrowing of the left ICA; (f–g) axial T1WI (FS, Gd) shows decreased wall thickening and resolution of wall enhancement of the same segments of ICA on both sides and (h) demonstrates significant interval improvement of the distension with normal enhancement of the cavernous sinuses on both sides and with no filling defects within. AIS = acute ischemic stroke; ICA = internal carotid artery; MRA = magnetic resonance angiography.

used) was based upon prior case reports of a child<sup>3</sup> and adult<sup>4</sup> with pneumococcal meningitis who progressed to AIS, both of whom were reported to show a beneficial response to subsequent corticosteroids. Currently, there are two ongoing clinical trials<sup>8,9</sup> evaluating the efficacy of high-dose corticosteroids in secondary stroke prevention in children with a focal cerebral arteriopathy-inflammatory type (FCA-I), which may share a common inflammatory pathophysiological underpinning to our case, although FCA-I is typically considered presumed viral in etiology.<sup>10</sup> In contrast to the above studies, our patient received corticosteroids for primary stroke prevention, given the stenosis seen at the petrous and cavernous portion of the bilateral ICAs. Concern was raised about the risk for either hypoperfusion-related ischemic stroke or hyperacute arterial stroke associated with thrombosis formation due to abnormal flow distal to the ICA narrowing. No restricted diffusion was evident on MRI in our case. While the effects of the multiple treatments cannot be teased apart (i.e., urgent sinus decompression surgery, IV antibiotics, therapeutic anticoagulation and high dose corticosteroids), we nevertheless demonstrate that the addition of corticosteroids was associated with a positive clinical and radiologic outcome and avoidance of an acute ischemic stroke. Further research is required into the underlying cause and optimal treatment of patients with pneumococcal-associated vasculopathy to ensure that treatment is standardized and that the risk of subsequent ischemic stroke is

considered in all patients with intracranial infection and inflammatory disease.

**Acknowledgments.** None.

**Author contributions.** RG – conceptualizing study, drafting and revising the manuscript. NW – drafting and revising the manuscript. MM – providing critical review of the manuscript. HM – conceptualizing study, drafting and revising the manuscript.

**Funding statement.** The authors have no relevant financial disclosures or conflicts of interest to report.

Written consent was obtained from the patient's parents.

**Competing interests.** The authors declare no conflict of interest.

## References

1. Dunbar M, Shah H, Shinde S, et al. Stroke in pediatric bacterial meningitis: population-based epidemiology. *Pediatr Neurol.* 2018;89:11–8. DOI: [10.1016/j.pediatrneurol.2019.09.005](https://doi.org/10.1016/j.pediatrneurol.2019.09.005).
2. Schut ES, Lucas MJ, Brouwer MC, Vergouwen MDI, van der Ende A, van de Beek D. Cerebral infarction in adults with bacterial meningitis. *Neurocrit Care.* 2012;16:421–7. DOI: [10.1007/s12028-011-9634-4](https://doi.org/10.1007/s12028-011-9634-4).
3. Mukherjee D, Saha A. Cerebral vasculitis in a case of meningitis. *Iran J Child Neurol.* 2017;11:81–4.
4. Khedher A, Sma N, Slama D, Fraj N, Hachfi W, Boussarsar M. Cerebral vasculitis complicating pneumococcal meningitis. *Eur J Case Rep Intern Med.* 2018;5:000819. DOI: [10.12890/2018\\_000819](https://doi.org/10.12890/2018_000819).

5. Pfister HW, Feiden W, Einhaupl KM. Spectrum of complications during bacterial meningitis in adults. Results of a prospective clinical study. *Arch Neurol*. 1993;50:575–81. DOI: [10.1001/archneur.1993](https://doi.org/10.1001/archneur.1993).
6. Schut ES, Brouwer MC, de Gans J, Forquin S, Troost D, van de Beek D. Delayed cerebral thrombosis after initial good recovery from pneumococcal meningitis. *Neurology*. 2009;73:1988–95. DOI: [10.1212/WNL.0b013e3181c55d2e](https://doi.org/10.1212/WNL.0b013e3181c55d2e).
7. Pugin D, Copin JC, Goodyear MC, Landis T, Gasche Y. Persisting vasculitis after pneumococcal meningitis. *Neurocrit Care*. 2006;4:237–40. DOI: [10.1385/NCC.4:3:237](https://doi.org/10.1385/NCC.4:3:237).
8. PASTA Trial. <https://www.pasta-trial.ch/the-pasta-trial/> [Accessed June 3, 2024]
9. FOCAS Trial. <https://nihstroketrials.org/trials/focas/home> [Accessed June 3, 2024]
10. Hui AWH, Yau MLY, Fung ELW, et al. Focal cerebral arteriopathy inflammatory type in a child – MD diagnosis using vessel wall imaging technique with review of classification and diagnostic evaluation criteria. *Radiol Case Rep*. 2023;18:3169–74. DOI: [10.1016/j.radcr.2023.05.067](https://doi.org/10.1016/j.radcr.2023.05.067).
11. D’Aniello S, Rustici A, Gramegna L, et al. The contribution of vessel wall magnetic resonance imaging to the diagnosis of primary and secondary central nervous system vasculitis. *Diagnostics*. 2024;14:9. DOI: [10.3390/diagnostics14090927](https://doi.org/10.3390/diagnostics14090927).
12. Chan OW, Lin JJ, Hsia SH, et al. Methylprednisolone pulse therapy as an adjuvant treatment of *Streptococcus pneumoniae* meningitis complicated by cerebral infarction – a case report and review of the literature. *Childs Nerv Syst*. 2020;36:229–33. DOI: [10.1007/s00381-019-04485-6](https://doi.org/10.1007/s00381-019-04485-6).