

9p TRISOMY: A NEW CASE DUE TO MATERNAL t(9;18) TRANSLOCATION

A. PRETO (1), E. LENZINI (1), P. DRIGO (2), G. FASOLI(3), A. DE PASCALE (4).

(1) Laboratory of Cytogenetics, Department of Pediatrics, University of Padova, Italy

(2) Department of Pediatrics, University of Padova, Italy

(3) Heart Surgery Center, University of Padova, Italy

(4) Pediatric Division, Camposanpiero Hospital, Padova, Italy

A case of a patient carrying a 9p trisomy due to a maternal t(9;18) (p13;p11) translocation is reported. In addition to the principal findings which characterize the 9p trisomy syndrome, this case presents some dysmorphic features due to the partial deletion of chromosome 18.

Since the first case of 9p trisomy described by Rethoré et al. (1970), several new cases have been reported, as listed in the references. Among recently identified syndromes due to autosomal aberrations, 9p trisomy is certainly the most frequent after Down's syndrome (Tenconi et al. 1976). We report a new case resulting from a maternal t(9;18) translocation.

CASE REPORT

The patient, first child of a 54-year-old father and a 34-year-old mother, was delivered by Cesarean after a full term pregnancy. Birth weight was 3200 g. The family history is negative for chromosomal and metabolic diseases. Cardiopathy was found at birth with presence of double vena cava, defect of the interventricular septum and persistence of arterial duct. At 2 months the following characteristics were noted: flat occiput, prominent parietal bones, large anterior fontanella (6 × 4 cm), broad osseous lacuna along the metopic suture, high and flat forehead, low hairline, arched eyebrows, hypertelorism with bilateral epicanthus, horizontal palpebral fissures, small and sunken eyeballs, large nose (especially at the tip) with a broad and prominent bridge, nostrils downwards and forwards. The philtrum was long and well developed, the upper lip short and thin, the lower lip protruding, the mouth angles were slanted downwards. The auricles were low-set with the helix folded onto a prominent anthelix; the concha was deep and broad. The neck was short. The hands appeared long with a clinodactyly of the fifth fingers. There was also a dorsal dislocation of second toes.

The auxological and psychomotor development were checked periodically. At 12 months weight,

height and head circumference were below the 3rd percentile (6700 g, 67 cm, 43 cm). These values evidenced microcephaly. At 30 months such relationships remained constant (8800 g, 78 cm, 46 cm). Neurological examination at 10 months revealed a child with poor miming (lower lip still even while crying), torpid pupillar reflexes, incoordinate ocular motility, involuntary attempts to catch and muscular hypotonia with inability to carry the head. At 18 months the child was unable to speak, seized objects, and was able to sit without support for only a few minutes. At 2½ years the child was able to sit down, but made no attempt to move; the Brunet-Lezine test revealed a development of 4 months.

Radiological examination

At 1 year the vertebral column revealed the presence of a left supernumerary cervical rib; the pelvis showed an increased distance between the trip-joint arches; absence of pubis, and numerous schisis of posterior arches at the cervical-lumbar level. The nucleus of pubis bones appeared at 2 years; skeletal development corresponded to that of a newborn.

EEG was normal.

At 26 months a cardiac catheterization showed a right ventricular hypertrofia, moderate pulmonary valvular stenosis and a interventricular defect.

Dermatoglyphic findings

Left hand: Single transverse palmar crease; axial triradius in t position; atd angle, 46°; hypothenar pattern, ulnar loop; digital triradii: a terminates at 5', b and c absent, d at 11.

Digital patterns: Ulnar loops on fingers 1-3-4-5, radial loop on 2.

Right hand: Normal palmar crease; axial triradius in t position; atd angle, 47°; hypothenar pattern:

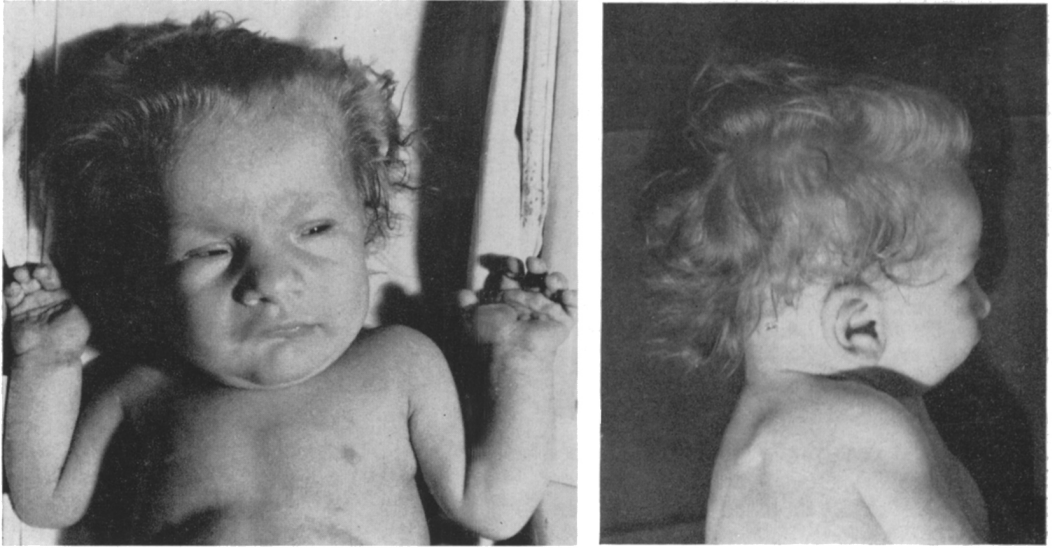

Fig. 1. The patient at 2 months of age.

Fig. 2. Maternal caryotype (R banding: BuDR acridine-orange).

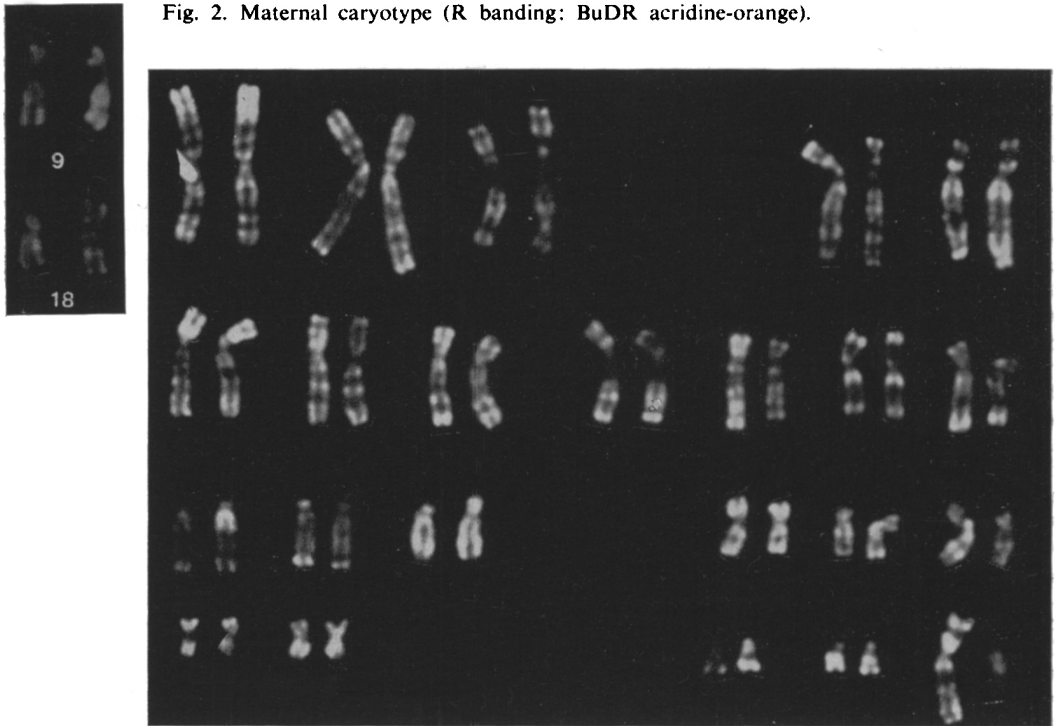


Fig. 3. The patient's caryotype (R banding: BuDR acridine-orange).

ulnar loop; digital triradii: *a* terminates at 5', *b* and *c* absent, *d* at 11.

Digital patterns: Radial loop on fingers 2-4 and ulnar loop on 1-3-5.

Cytogenetic investigations

Chromosome preparations from peripheral blood cultures of the patient with R-banding technique revealed a karyotype with 46 chromosomes, but the short arm of chromosome 18 had a supernumerary chromatinic material identified as the short arm of chromosome 9.

Chromosome analysis of the parents revealed that the mother carried a reciprocal translocation between the short arm of chromosome 9 and the short arm of chromosome 18.

The maternal karyotype was: 46,XX,t(9;18)(p13;p11). The karyotype of the child was determined by a segregation type adjacent-1: 46,XY,+der(18),t(9;18)(p13;p11)mat.

Therefore the child is trisomic for the short arm of chromosome 9 and monosomic for a part of the short arm of chromosome 18 (p11→ter).

DISCUSSION

According to previous report, the main clinical features of 9p trisomy are the following: severe mental retardation, bone growth retardation, large and bulbous nose, small and sunken eyeballs, low-set ears and large auricles, downwards slanting mouth angles, clinodactyly of the fifth fingers, long palm and brachymesophalangy, single palmar crease, and triradii band *c* absent or fused. By means of cytogenetic data it is possible to distinguish for this syndrome a pure 9p trisomy and an associated 9p trisomy.

The pure 9p trisomy is characterized by a phenotype corresponding to the above-mentioned features, in which the defect consists of a trisomy of the short arm of chromosome 9.

The associated 9p trisomy is characterized by the presence of multiple malformations of different organs and by a karyotype in which trisomy of the short arm of chromosome 9 is accompanied by a partial monosomy of another chromosome. Usually trisomy is due to a familial balanced translocation between the short arm of chromosome 9 and an acrocentric chromosome. The syndrome rarely arises "de novo".

Our case is undoubtedly due to an associated 9p trisomy, for the phenotypical features and for the presence of a partial monosomy of the short arm of chromosome 18, probably causing some malformations such as cardiopathy.

Somatic and psychomotor follow up led to the conclusion that this syndrome is caused by a serious cerebropathy with a more severe prognosis than any other chromosomal syndrome.

REFERENCES

- Baccichetti C., Tenconi R. 1973. A new case of trisomy for the short arm of no. 9 chromosome. *J. Med. Genet.*, 10: 296-299.
- Balicek P., Zizka J., Licky J. 1975. A case of trisomy 9p in a family with translocation 9/15. *Human-genetik*, 7: 353-358.
- Blank C.E., Colver C.B., Potter A.M., McHugh J., Lorber J. 1975. Physical and mental defect of chromosomal origin in four individuals of same family. Trisomy for the short arm of 9. *Clin. Genet.*, 7: 261-273.
- Canki N., Rethoré M.O., Ferrand J., Lejeune J. 1973. Trisomie 9p par t(9p;14q) de novo. *Genetika*, 38: 293-297.
- Cantù J.M., Buentello L., Armendares S. 1971. Trisomie Cp: un nouveau syndrome. *Ann. Génét.*, 14: 177-186.
- Casperson T., Zech L., Johansson C., Medest E.J. 1970. Identification of human chromosomes by DNA-binding fluorescent agents. *Chromosoma*, 30: 215-227.
- Centerwall W.R., Mayescki C.A., Cha Chul 1975. Trisomy 9q-. A variant of the 9p trisomy syndrome. *Humangenetik*, 29: 91-98.
- Centerwall W.R., Miller K.S., Reeves L.M. 1976. Familial "partial 9p" trisomy: six cases and four carriers in three generations. *J. Med. Genet.*, 13: 57-61.
- Chiyo H., Furuyama J., Suchara N., Obashi Y., Kikkawa H., Ikama F. 1976. 9p trisomy identified by Giemsa-11. *Hum. Genet.*, 32: 217-220.
- Dallapiccola B., Mazzilli C., Bollea G., Gandini E. 1976. Complex translocation t(9;21)(9;22)(q12;p13)(q12;q11) in the family of a child with 9p trisomy syndrome. *Hum. Genet.*, 33: 73-76.
- Dinno N., Silvey G.L., Weisskopf B. 1974. 47,XY,t(9p+;11q+) in a male infant with multiple malformation. *Clin. Genet.*, 6: 125-131.
- Dutrillaux B., Lejeune J. 1971. Sur une nouvelle technique d'analyse du caryotype humain. *C. R. Acad. Sci. (Paris)*, 272: 2638-2640.
- Dutrillaux B., Laurent C., Couturier J., Lejeune J. 1973. Coloration par l'acridine-orange de chromosomes préalablement traités par le 5-bromo-déoxyuridine (BrdU). *C. R. Acad. Sci. (Paris)*, 276: 3179-3181.

- Ebbin A., Wilson M.G., Towner J., Slauter J. 1973. Prenatal diagnosis of an inherited translocation between chromosome n. 9 and 18. *J. Med. Genet.*, 10: 65-69.
- Fujita H., Abe T., Furuyama J. 1974. Three cases of partial trisomy 9p. *Jap. J. Hum. Genet.*, 19: 84-85.
- Fujita H., Abe T., Yamamoto K., Furuyama J. 1974. Possible complex translocation t(9;14;13)(q12;p13;q31) in mother of a child with 9p-trisomy syndrome. *Humangenetik*, 25: 83-92.
- Gerald P.S., Wertelecki W. 1971. The syndrome of trisomy for the short arm of chromosome 9, confirmed by fluorescence microscopy. *Pediatr. Res.*, 5: 645-650.
- Germain D., Philippe N., Hermier M., Licheron A., Requine H., Pincon J.A. 1975. Trisomie pour les bras courts du chromosome 9. (Syndrome +9p). A propos d'une observation par translocation mat. 9/22. *Lyon Medical*, 233: 227-230.
- Gripemberg V., Hongell K., Livanainen M., Kivimaki T. 1977. Free trisomy 9p in an elderly woman. *Ann. Genet.*, 1: 36-40.
- Gustavson K.H., Wahlström J. 1977. Trisomy 9p syndrome and XYY syndrome in siblings. *Clin. Genet.*, 11: 67-72.
- Hoehn H., Engel W., Reinwein H. 1971. Presumed trisomy for the short arm of chromosome no. 9 not due to inherited translocation. *Humangenetik*, 12: 175-181.
- Howard-Peebles P.N., Yarbrough K.M., Stoddard G.R., Rary J.M. 1977. Translocation 9q/13q resulting in duplication (trisomy 9pter—9q22) and deficiency (monosomy 13pter—13q12). *Clin. Genet.*, 11: 46-52.
- Jacobsen P., Hobolt N., Mikkelsen M. 1975. Trisomy 9p in a patient with de novo 9/15 translocation. *Clin. Genet.*, 7: 317-324.
- Kaosaar M.E., Mikelsaar A.V.N., Talvik T.A., Mikelsaar R.V.A. 1976. A case of trisomy for the short arm of cr. 9 (+9p). *Hum. Genet.*, 34: 77-80.
- Kardon N.B., Salwen H.B., Krauss M.A., Davis J.G., Jenkins E.C. 1977. De novo trisomy 9pter—q13. *Hum. Genet.*, 37: 149-153.
- Lin C.C., Holman G., Sewell L. 1974. Translocation t(9;11)(p13;p15) and trisomy 9p syndrome. *Am. J. Hum. Genet.*, 26: 54A.
- Lurie I.W., Lzjiuk G.I., Gurevich D.B., Usoev S.S. 1976. Genetics of the +9p syndrome. *Hum. Genet.*, 32: 23-33.
- Mason M.K., Spencer A., Rutter A. 1975. A case of partial (9p) trisomy in a family with balanced translocation 46,XX,t(1p+;9q-). *J. Med. Genet.*, 12: 310-314.
- Mastroiacovo P., Dallapiccola B., Gugliantini F., Segni G. 1976. Trisomia 9p da traslocazione paterna t(6;9)(q27;p13). *Riv. Ital. Ped. (I.J.P.)*, 2: 115-123.
- Mulcahy M.T., Jenkyn J. 1975. The 9p trisomy syndrome: two further cases arising from different familial translocation. *Clin. Genet.*, 8: 199-204.
- Orye E., van Egmond H., Devloo-Blacquart A. 1975. A new case of the trisomy 9p syndrome. Report of a patient with unusual chromosome findings (46,XX/47,XX,i9p) and a peculiar heart defect. *Clin. Genet.*, 7: 134-143.
- Penchaszadeh V.B., Coco R. 1975. Partial 9 trisomy by 3:1 segregation of a balanced maternal translocation (7q+; 9p-). *J. Med. Genet.*, 12: 301-305.
- Podruch P.E., Weisskopf B. 1974. Trisomy for the short arm of chromosome 9 in two generations with balanced translocations t(15p+;9q-) in three generations. *J. Pediatr.*, 85: 92-95.
- Rethoré M.O., Larget-Piet L., Abonyi D. 1970. Sur quatre cas de trisomie pour le bras court du chromosome 9. Individualisation d'une nouvelle entité morbide. *Ann. Génét.*, 13: 217-232.
- Rethoré M.O., Hoehn H., Rott H.D., Couturier J. 1973. Analyse de la trisomie 9p par dénaturation ménagée. A propos d'un nouveau cas. *Humangenetik*, 18: 129-138.
- Rethoré M.O., La Fourcade J. 1974. Trisomie du bras court du chromosome 9: syndrome +9p. *Journ. Paris. Pédiat.*, 379-390. Paris: Flammarion.
- Rethoré M.O., Ferrand S., Dutrillaux B., Lejeune J. 1974. Trisomie 9p par t(4;9)(q34;q21)mat. *Ann. Génét.*, 17: 157-161.
- Schinzel A., Hayashi K., Schmid W. 1975. Trisomy 9p due to paternal translocation t(9;13)(q13;q12). *Humangenetik*, 30: 307-316.
- Schwanzitz G., Schamberger U., Rott H.D., Wiczorek V. 1974. Partial trisomy 9 in the case of familial translocation by 8/9 mat. *Ann. Génét.*, 17: 163-166.
- Stoll C., Levy J.M., Gardea A. 1975. Trisomy 9p in a girl whose mother has a translocation t(9;20)(q12;p13). *Humangenetik* 27: 269-274.
- Tarantino E., Giorgi P.L., Fiori B. 1977. Trisomia 9p con peculiarità radiologiche e citogenetiche. *Acta Med. Auxol.*, 9: 165-166.
- Tenconi R., Baccichetti C. 1976. La sindrome da trisomia 9p. *Prosp. Pediat.*, 22: 221-227.
- Turleau C., de Grouchy J., Chavin-Colin F., Roubin M., Langmaid M. 1974. Trisomie 9p: deux nouvelles observations. *Ann. Génét.*, 17: 167-174.
- Turleau C., de Grouchy J., Roubin M., Chavin-Colin F., Cachin O. 1975. Trisomie 9p pure 47,XX+del(9)(q11). Découverte d'une cellule 46,XY,del(9)(q11) chez le père. *Ann. Génét.*, 18: 125-129.
- Wyandt H.E., Hecht F., Magenis R.E., Wysham D.G., Prescott G. 1976. 9p trisomy identified by Giemsa-11. *Hum. Genet.*, 32: 217-220.
- Zaremba J., Zdzienicka E., Glogowska I., Abramowicz T., Taracha B. 1974. Four cases of 9p trisomy resulting from a balanced familial translocation t(9;15)(q13;q11). Clinical picture and cytogenetic findings. *J. Ment. Defic. Res.*, 18: 153-190.

Dr. A. Preto, Servizio di Citogenetica, Clinica Pediatrica, Università di Padova, Italy.