

## Case Report

**Cite this article:** Fabiani N, Heath-Freudenthal A, Von Alvensleben I, Echazú G, Freudenthal F, and Rothman A (2025) Use of a ductal occluder device as a test and then permanent closure of a large ductus arteriosus with increased pulmonary vascular resistance: a case report. *Cardiology in the Young* 35: 1283–1286. doi: [10.1017/S1047951125001726](https://doi.org/10.1017/S1047951125001726)

Received: 22 January 2025  
Accepted: 7 March 2025  
First published online: 13 May 2025



### Keywords:

Ductus arteriosus; pulmonary arterial hypertension; cardiac catheterisation; device closure

### Corresponding author:

Nelly Fabiani;  
Email: [fabiani.hurtado@gmail.com](mailto:fabiani.hurtado@gmail.com)

# Use of a ductal occluder device as a test and then permanent closure of a large ductus arteriosus with increased pulmonary vascular resistance: a case report

Nelly Fabiani<sup>1</sup> , Alexandra Heath-Freudenthal<sup>2</sup> , Inge Von Alvensleben<sup>2</sup>, Gabriel Echazú<sup>1</sup>, Franz Freudenthal<sup>2</sup> and Abraham Rothman<sup>3</sup>

<sup>1</sup>Department of Pediatrics, Centro Médico Quirúrgico Boliviano Belga, Cochabamba, Bolivia; <sup>2</sup>Kardiozentrum, La Paz, Bolivia and <sup>3</sup>Department of Pediatrics, University of Nevada Las Vegas and Children's Heart Center, Las Vegas, NV, USA

## Abstract

A 3-year-old girl with a large ductus arteriosus had increased pulmonary vascular resistance at cardiac catheterisation. Test occlusion of the ductus arteriosus with a Nit-Occlud PDA-R device and hyperoxia decreased the pulmonary arterial pressure to < 50% of systemic level. The ductus was closed with the same device. Two years later, an echocardiogram showed normal pulmonary arterial pressure.

## Case report

During an outreach clinic, a 7 month-old-girl from the city of Cobija, Bolivia (228 m above sea level), was diagnosed with a large ductus arteriosus by echocardiography. She had recurrent pneumonias and failure to thrive. At 3.5 years of age, she was re-evaluated in the city of Cochabamba (2558 m above sea level). Her weight was 10 Kg (< 1 percentile), length was 88 cm (< 1 percentile), and oxygen saturation in room air was 88%. She had a systolic murmur in the left infraclavicular area, a loud second heart sound, and bounding femoral pulses. An echocardiogram showed a large ductus arteriosus, with an estimated diameter of 7 mm at the pulmonary end, a left to right shunt only in systole with a gradient of 10 mmHg, dilatation of left cardiac chambers, and a tricuspid regurgitation jet velocity of 5 metres/second.

Cardiac catheterisation was performed with two femoral venous 5F sheaths and one arterial 4F sheath. Heparin (50 U/kg) and Cefazolin (30 mg/kg) were administered. Baseline hemodynamics were obtained (Table 1). The minimum diameter of the ductus by angiography was 8 mm. Temporary test occlusion of the ductus was performed using a Nit-Occlud PDA-R (PFM, La Paz, Bolivia) device (minimum stent diameter of 11 mm, Ref # 160117), while simultaneously delivering 100% FiO<sub>2</sub> for 30 minutes. Haemodynamic measurements were repeated (Table 1). With a reduction in pulmonary arterial pressure to less than 50% of systemic level, the device was released; there was a trivial residual central shunt.

After the procedure, the patient was started on sildenafil (1.25 mg/kg/dose three times a day). At 48 hours, an echocardiogram showed an estimated right ventricular systolic pressure of 56 mmHg; the sildenafil dose was doubled. Four days later, the estimated right ventricular systolic pressure was 38 mmHg. The oxygen saturation was 93% on room air, and the patient was discharged.

The patient returned to her hometown. An echocardiogram 3 months later showed no change in estimated right ventricular systolic pressure. Echocardiograms at 1 and 2 years after the procedure demonstrated an estimated systolic right ventricular pressure of 30 mmHg or less. She was doing very well clinically.

## Discussion

Interventional catheterisation for ductus arteriosus is now first-line treatment in patients ranging from very small premature infants to patients in the ninth decade of life.<sup>1</sup> In some patients with a nonrestrictive ductus arteriosus, the increased flow and pressure to the pulmonary circulation can lead to elevated pulmonary vascular resistance. However, this is unusual in children < 2 years of age without associated cardiac or non-cardiac abnormalities.<sup>2</sup>

Increased pulmonary vascular resistance constitutes a therapeutic dilemma. Closure of the ductus arteriosus may not prevent progressive pulmonary vascular disease and right heart failure, and some patients may exhibit worse symptoms than they would have if the PDA had remained open.<sup>3</sup> Vasoreactivity testing and the advent of “pulmonary hypertension

**Table 1.** Cardiac catheterisation data

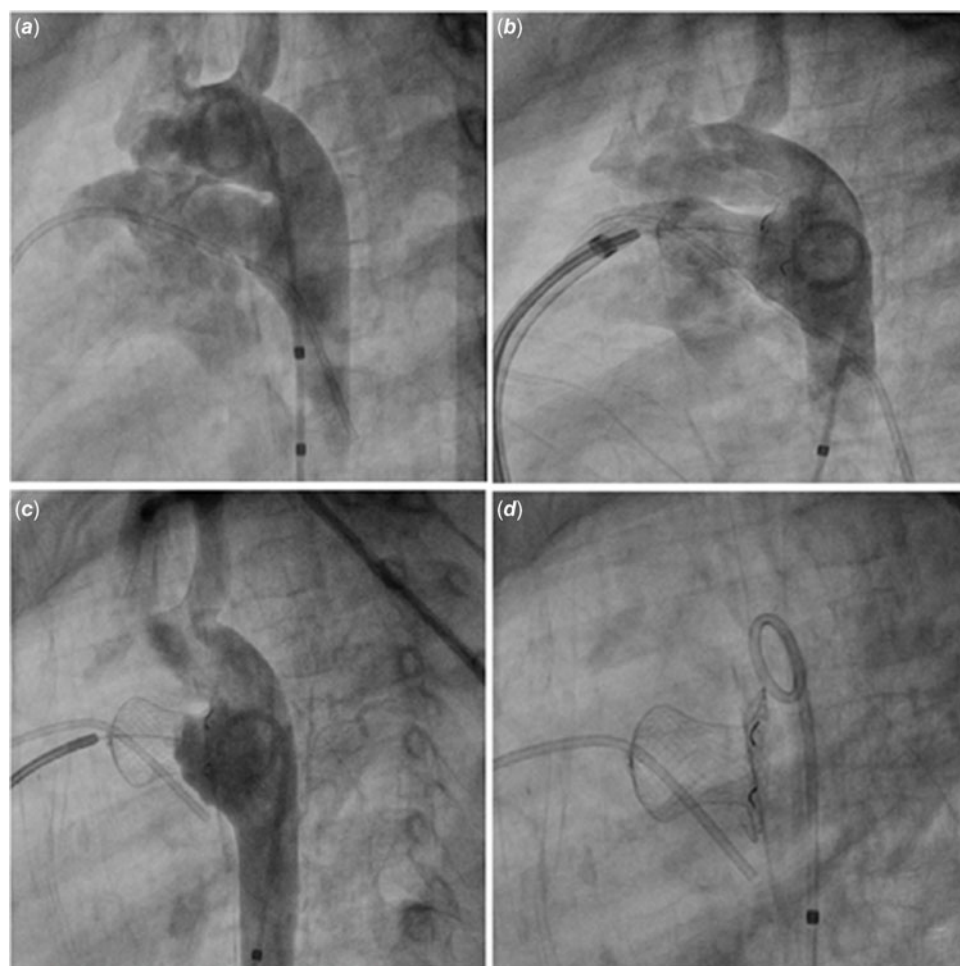| Parameter                 | Basal      | Temporary occlusion<br>+ FiO <sub>2</sub> 100% |
|---------------------------|------------|--|
| <b>Pressures (mmHg)</b>   |            |  |
| Right atrium              | (3)        | (5)  |
| Right pulmonary artery    | 76/41 (53) | 46/11 (26)                                     |
| Aorta                     | 82/45 (63) | 76/44 (66)                                     |
| Right wedge pressure      | (6)        | (7)  |
| <b>Calculations</b>       |            |  |
| Qp/Qs                     | 1.4        | 1.4  |
| PVRI (WU/m <sup>2</sup> ) | 10.4       | 5.4  |
| SVRI (WU/m <sup>2</sup> ) | 19.3       | 24.4   |
| PVRI/SVRI                 | 0.54       | 0.22   |

Abbreviations: FiO<sub>2</sub> = inspired oxygen; Qp = pulmonary flow; Qs = systemic flow; PVRI = pulmonary vascular resistance index; SVRI = systemic vascular resistance index; WU/m<sup>2</sup> = Wood units per square metre of body surface area; ( ) = mean pressure.

medications” that can be used before and/or after intervention have added levels of complexity to the treatment decision.<sup>4</sup> While there are no perfect criteria for when to intervene (by percutaneous devices or surgery), a combination of clinical, imaging, and haemodynamic parameters is used to predict the probability of favourable short-term results.<sup>5</sup>

Recommended thresholds for ductus arteriosus repair in the presence of pulmonary hypertension have included: a baseline pulmonary vascular resistance of < 4 WU/m<sup>2</sup> and pulmonary-to-systemic vascular resistance ratio of < 0.3–0.33.<sup>6</sup> Conversely, defect repair has been contraindicated when there is a pulmonary vascular resistance index of > 8 WU/m<sup>2</sup> or a pulmonary vascular resistance of > 4.6 WU. Parameters in between these extremes have required individualised evaluation, often with pulmonary vaso-reactivity testing.<sup>5</sup>

Temporary occlusion of the ductus arteriosus, generally with a balloon catheter, allows the acute evaluation of its effect on pulmonary arterial pressure, particularly in borderline cases.<sup>7</sup> The use of an interventional device instead of a balloon for temporary



**Figure 1.** Images of the cardiac catheterization procedure. (a) Angiogram demonstrating the ductus arteriosus. (b) Placement of the device in the ductus arteriosus. (c) Angiogram after 30 minutes of test occlusion and hyperoxia, device still attached. (d) The device after release.

**Table 2.** Device closure of hypertensive ductus arteriosus: studies in paediatric patients

| Study                             | No. of patients           | Age range                    | Baseline PAP mmHg            | Highest PVRI WU/m <sup>2</sup> | Devices  | Time of follow-up | Procedural/Clinical Outcome  |
|-----------------------------------|---------------------------|------------------------------|------------------------------|--------------------------------|--|-------------------|--|
| Niu et al. <sup>11</sup>          | 6 (from 7)                | 1.7 mo – 12.2 y (median 2 y) | 48-90 (PAP:SP 71 – 96%)      | 13.2                           | ADO, AMVSDO, coil  | 4 - 46 mo         | 2 = resolution of PH.<br>5 = persistent RV hypertension - remain on PH therapy.  |
| Salavitarbar et al. <sup>12</sup> | 33                        | 8.8–23.8 mo (median 14.5 mo) | mean 49 (PAP: SP mean 61.6%) | 11.1                           | ADO, coil, Amplatzer Vascular Plug II, Amplatzer Vascular Plug, Nit-Occlud PDA | 1 - 63.4 mo       | 3 = device complications.<br>1 = cardiac arrest (likely PAH crisis), death 6 mo after closure.<br>75% weaned or discontinued PH therapy. |
| Sadiq et al. <sup>13</sup>        | 43 (from 45)              | 2 – 27 y (median 10 y)       | mean 79                      | 17.2                           | ADO, AMVSDO, ASO   | 41 - 151 mo       | 4 = persistent severe pulmonary hypertension (median follow-up 80 mo).   |
| Zabal et al. <sup>14</sup>        | 168 (81.5% were children) | 2 mo – 59 y (mean 10.3 y)    | mean 60                      | 9.4                            | ADO, AMVSDO, ASO, Gianturco-Grifka (Cook Inc., Bloomington, IN, USA)           | 37.1 ± 24 mo      | 5 = device embolisation,<br>1 = descending Ao obstruction.<br>>90% normalisation of PAP.   |

Abbreviations: Ao = aorta; PVRI = pulmonary vascular resistance index; WU/m<sup>2</sup> = Wood units per square metre of body surface area; mo = months; y = years; PAP = pulmonary arterial pressure; SP = systemic pressure; PH = pulmonary hypertension; RV = right ventricle; ADO = Amplatzer Duct Occluder; AMVSDO = Amplatzer Muscular Ventricular Septal Defect Occluder; ASO = Amplatzer Septal Occluder (AGA Medical Corporation, Plymouth, Minneapolis, United States of America).

occlusion testing is effective and safe, and it offers the advantage of avoiding an extra step, as well as reducing the cost of the procedure in resource-limited settings. This was demonstrated in adult patients by Yan et al, using Amplatzer duct occluder and Amplatzer muscular ventricular septal defect occluder (ADO and AMVSDO, AGA Medical Corporation, Golden Valley, Minnesota, USA) devices.<sup>8</sup>

The parameters that have been considered favourable for closure after performing vasoreactivity testing or temporary ductus occlusion have included: a decrease of 20% in the pulmonary vascular resistance, a decrease of 20% in the pulmonary-to-systemic vascular resistance ratio, a pulmonary vascular resistance < 6 WU/m<sup>2</sup> or a final resistance ratio < 0.3.<sup>9</sup> Patients with a pulmonary vascular resistance > 9 WU/m<sup>2</sup>, breathing 100% oxygen, have been considered poor candidates for defect repair.<sup>10</sup> Table 2 summarises the experience of several investigators in paediatric patients with hypertensive ductus arteriosus.<sup>11–14</sup>

Our patient was diagnosed with a large ductus arteriosus at an early age and at low altitude. She underwent a catheterisation at higher altitude, where she had an elevated pulmonary vascular resistance. A Nit-Occlud PDA-R device was used to perform the temporary occlusion test (keeping it attached to the cable) simultaneously with hyperoxia. There was a significant decrease in pulmonary arterial pressure. The same device, which had a minimum stent diameter 3 mm larger than the ductus diameter, was released and remained in stable position. The estimated pulmonary pressure by echocardiography was normal at

the two-year visit, at which time the sildenafil was discontinued. The contribution of her return to live near sea level with respect to her normalisation of pulmonary arterial pressure remains unclear.

Our patient had a significant drop in pulmonary arterial pressure with temporary device test occlusion and we proceeded with device release. However, the exact threshold criteria for when to proceed with closure of hypertensive ductus arteriosus remain to be determined. Experience with larger numbers of patients who have vasodilator testing, temporary occlusion, and treatment with pulmonary hypertension medications before and after intervention will be necessary to better determine the criteria for ductal closure.

**In conclusion,** we describe successful use of a device to temporarily test-occlude and then permanently close a hypertensive ductus arteriosus in a 3-year-old patient.

**Acknowledgements.** None.

**Financial support.** The Herzverein Foundation and Gift of Life International funded the outreach visits and the cardiac procedure.

**Competing interests.** F. Freudenthal is Chief Executive Officer of PFM SRL, Bolivia.

A. Heath-Freudenthal and I. Von Alvensleben are consultants of PFM SRL, Bolivia.

**Ethical standard.** This study does not involve human experimentation.

## References

1. Galezcka M, Szkutnik M, Bialkowski J, et al. Transcatheter closure of patent ductus arteriosus in elderly patients: initial and one-year follow-up results—Do we have the proper device? *J Intervent Cardiol* 2020; 2020: 4585124.
2. Khositseth A, Wanitkun S. Patent ductus arteriosus associated with pulmonary hypertension and desaturation. *Cardiol J* 2012; 19: 543–546.
3. Rigby ML. Closure of a large patent ductus arteriosus in adults: first do no harm. *Heart* 2007; 93: 417–418.
4. Myers PO, Tissot C, Beghetti M. Assessment of operability of patients with pulmonary arterial hypertension associated with congenital heart disease: – Do we have the good tools to predict success? *Circ J* 2014; 78: 4–11.
5. Rosenzweig EB, Abman SH, Adatia I, et al. Paediatric pulmonary arterial hypertension: updates on definition, classification, diagnostics and management. *Eur Respir J* 2019; 53: 1801916.
6. Balzer DT, Kort HW, Day RW, et al. Inhaled nitric oxide as a preoperative test (INOP test I): the INOP test study group. *Circulation* 2002; 106: 76–81.
7. Bhalgat P, Pinto R, Dalvi B. Transcatheter closure of large patent ductus arteriosus with severe pulmonary arterial hypertension: short and intermediate term results. *Ann Pediatr Cardiol* 2012; 5: 135–140.
8. Yan C, Zhao S, Jiang S, et al. Transcatheter closure of patent ductus arteriosus with severe pulmonary arterial hypertension in adults. *Heart* 2007; 93: 514–518.
9. Lopes AA, Barst RJ, Haworth SG, et al. Repair of congenital heart disease with associated pulmonary hypertension in children: What are the minimal investigative procedures? Consensus statement from the Congenital Heart Disease and Pediatric Task Forces, Pulmonary Vascular Research Institute (PVRI). *Pulm Circ* 2014; 4: 330–341.
10. Vijayalakshmi IB, Setty N, Narasimhan C, et al. Percutaneous device closure of patent ductus arteriosus with pulmonary artery hypertension: long-term results. *J Intervent Cardiol* 2014; 27: 563–569.
11. Niu MC, Mallory GB, Justino H, et al. Treatment of severe pulmonary hypertension in the setting of the large patent ductus arteriosus. *Pediatrics* 2013; 131: e1643–e1649.
12. Salavitarab A, Krishnan US, Turner ME, et al. Safety and outcomes of transcatheter closure of patent ductus arteriosus in children with pulmonary artery hypertension. *Tex Heart Inst J* 2020; 47: 250–257.
13. Sadiq M, Rehman AU, Hyder N, et al. Intermediate- and long-term follow-up of device closure of patent arterial duct with severe pulmonary hypertension: factors predicting outcome. *Cardiol Young* 2017; 27: 26–36.
14. Zabal C, García-Montes JA, Buendía-Hernández A, et al. Percutaneous closure of hypertensive ductus arteriosus. *Congenit Heart Dis Heart* 2010; 96: 625–629.